

CASE REPORT

Improved retention of ocular prosthesis with modified shallow socket impression technique

Andri Sinulingga, Putri Welda Utami Ritonga,* Haslinda Z. Tamin

ABSTRACT

Keywords: Custom ocular tray, Enucleation, Ocular prosthesis, Post enucleation

Background: The long-term use of a custom ocular prosthesis that is not replaced could cause a shallow socket. These changes affect the size of the socket. In fact, the custom ocular prosthesis becomes loose. **Objectives:** Modify the impression by duplicating the old custom ocular prosthesis as a special tray for obtaining an accurate impression of the socket and reducing clinical visits. **Case Report:.** A 42-year-old woman came to Dental Hospital Universitas Sumatera Utara with the chief complaint that the custom ocular prosthesis was easy to fall off and painful during movement. She has worn the ocular prosthesis for over 30 years, fabricating it five times. However, the last ocular prosthesis lasted for 10 years. The definitive impression was prepared by duplicating the custom ocular prosthesis, and this special tray was modified by adding a rod with a light body material due to its low viscosity. As a result of using the special tray, a more accurate impression can be made due to the small size of the rod. **Conclusion:** The impression technique with a modified tray from the duplicated old custom ocular prosthesis can record the eye socket in detail and produces a retentive custom ocular prosthesis. (IJP 2024;5(2):119-123)

Introduction

Eye loss has a major impact on the patient's physical and psychological. These conditions can also affect a person's social and professional life.¹ Eye loss can be caused by trauma, injury and congenital defects. Rehabilitation in this case is quite challenging because it must produce the same visualization in color, shape, contour and orientation to get a realistic appearance.^{2,3} Cosmetic rehabilitation with specially made prosthetic can provide social acceptance for the individual and reduce the problems caused.¹

Enucleation is the removal of the entire eyeball after the extraocular muscle and optic nerve have been transected.^{3,4} This is the last procedure most often performed when the patient has intraocular malignancy, trauma, and painful eye blindness. After enucleation, the orbital volume is lost because the orbital tissue that once supported and protected the natural eye is no longer useful and tends to shrink. Cosmetic abnormalities arising from loss of orbital volume after eye enucleation include enophthalmos, upper eyelid ptosis, deepening of the superior sulcus, backward tilt of the ocular prosthesis, and drooping lower eyelid, i.e. ectropion. These symptoms, which are summarized in 'post-enucleated socket syndrome,' can appear separately or in combination and vary in severity.^{1,5,6}

Implant is the most common method of replacing lost volume in the socket after evisceration or enucleation.⁶ Although an implant is the best option, this treatment is expensive and cannot be done by everyone. Fabrication using a custom ocular prosthesis with various fabricating modifi-

cations can be the best alternative treatment option. It because the technique of making a custom ocular prosthesis able to duplicate the anatomy of the eye socket well.⁴ Thus, the results in an ocular prosthesis is more precise, well adapted and more aesthetically pleasing.⁷ These results provide a better cosmetic appearance and long-term comfort, because the use of a custom ocular prosthesis allows an even distribution of space in the socket.¹

One of the successes in fabricating a custom ocular prosthesis is the accurate impression of the anatomic area of the eye socket.^{3,4} Miller argues that the use of a custom ocular prosthesis is necessary as a tray in certain situations. This method involves the attachment of a solid suction rod to the patient's existing custom ocular prosthesis.³ The use of the old custom ocular prosthesis as a custom impression tray because the shape of the intaglio surface has not undergone significant changes to the socket. This case report will describe the prosthetic correction of post-enucleation syndrome by modifying a custom ocular prosthesis as a custom tray.

Case Report

A 42-year-old woman came to the Dental Hospital Universitas Sumatera Utara with the main complaint of loose, detached, and uncomfortable ocular prosthesis. The patient has worn the custom ocular prosthesis for 10 years. The patient had to press her ocular prosthesis

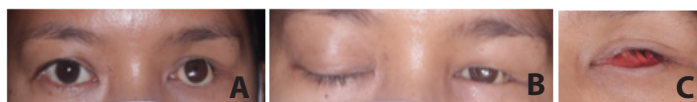

Figure 1. Clinical examination, A. While the old custom ocular prosthesis is used and the patient is asked to look forward, B. when closing the eyes, C. eye sockets of patients without ocular prosthesis

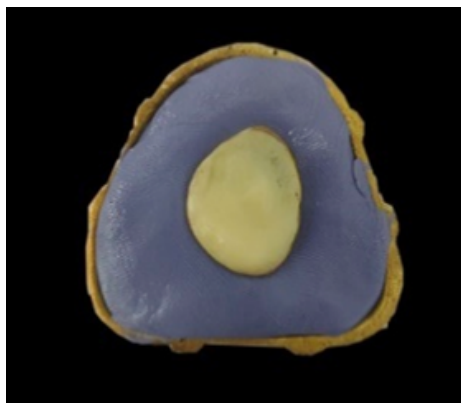


Figure 2. Duplication of the old custom ocular prosthesis

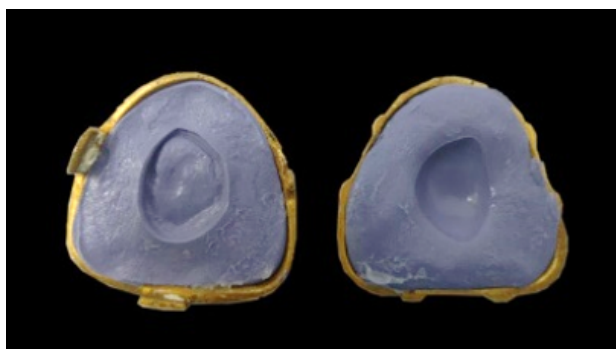


Figure 3. Triangulation

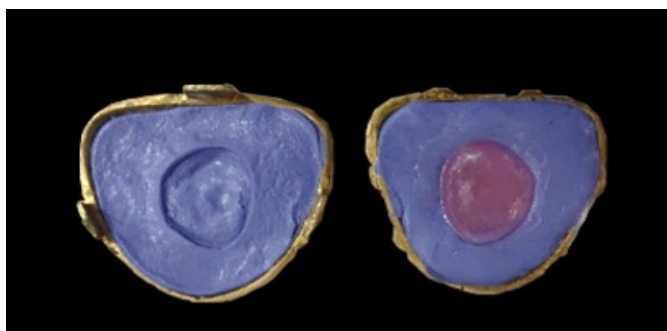


Figure 4. Duplicate using self-cure

to maintain it from falling out of the eye socket. The patient feels pain in the head region when pressing the ocular prosthesis, so the patient always takes analgetics. Patient also feels discomfort during daily usage of ocular prosthesis.

The cause of the loss of the left eyeball was due to being shot by a toy gun at the age of 9 years. The surgery was performed twice. The first surgery was performed to remove the entire eyeball, and the second surgery was performed to remove the cicatricial tissue that interfered with the retention and stabilization of the custom ocular prosthesis. During these 30 years, the patient has made 5 different custom ocular prosthesis. From the clinical examination, the patient was diagnosed with post-enucleated left anophthalmic socket. The size of the old custom ocular prosthesis looks large and protrudes when in use. This condition also makes it difficult for the eyelids to close. The prosthesis is not retentive and often slips out of the socket during use.

Anatomical impressions were not performed, custom impression tray were made using the patient's old custom ocular prosthesis. A custom tray was made by duplicating the old ocular prosthesis using a putty (Putty I-SiLTM Vinyl Poly Siloxane Impression Material, Spident CO., LTD, Korea) figure 2. The impression model was obtained from the impression figure 3. The impression was poured with self-curing acrylic (Self Curing Vertex®, Vertex-Dental B.V., Netherland) to duplicate the old ocular prosthesis to be used as a custom impression tray figure 4. Making the handle of an impression tray using self-cured acrylic by forming it in the shape of a rod and attaching it to the duplicated ocular prosthesis. The intaglio edge of the ocular prosthesis surface was reduced by ± 2 mm.

A custom impression using a vinyl poly siloxane light body (Light Body I-SiL vinyl poly siloxane impression material, Spident CO., LTD, Korea) figure 5, Petroleum jelly (Vaseline Repairing Jelly, A Unilever, Indonesia) was applied on skin around the left eye to avoid the impression material attaching to the eyelashes. The impression tray was coated with an adhesive tray (Extreme Adhesive, Medicept UK LTD, United Kingdom). The impression material is applied to the eye socket and on the surface of the impression tray. The impression tray is gently inserted into the eye socket to prevent forming bubbles in the mold. The patient was asked to close and move the eye in all directions, so that the impression material flows across the surface of the eye socket. The impression was checked to make sure all parts were recorded figure 6.

Making a physiological model by pouring the mold using a type IV plaster (Snow Rock Die Stone Gold, DK Mungyo, Korea). The next stage is making the scleral wax pattern and try in sclera wax. The mold was poured with wax (Anchor Brand Teeth Modeling Wax, Indonesia). The wax pattern is inserted into the patient's eye socket. Modify the size and shape according to the socket until the palpebral fissure and anterior curvature of the eye are similar to the contralateral eye. This trial of the scleral wax pattern was aimed to evaluate size, comfort, superior and inferior palpebrals support, and eye movements figure 7.

After the trial of the scleral wax pattern was obtained, it was continued by determining the color of the sclera using a shade guide. The curing was carried out using heat cure acrylic (Acrylic Denture Materials, Tricodent, England). The acrylic resin sclera was tried in the

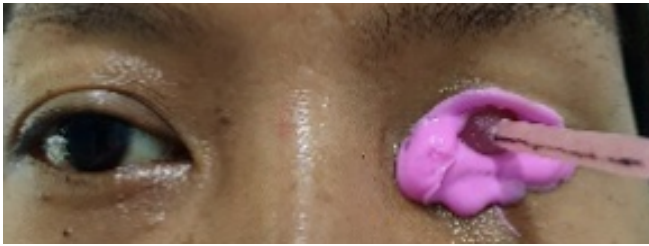


Figure 5. Custom impression

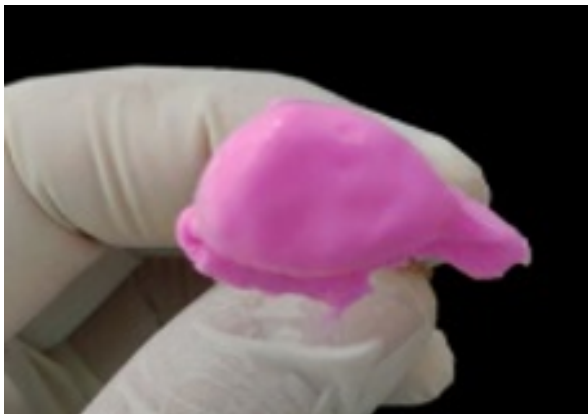

Figure 6. The result of impression

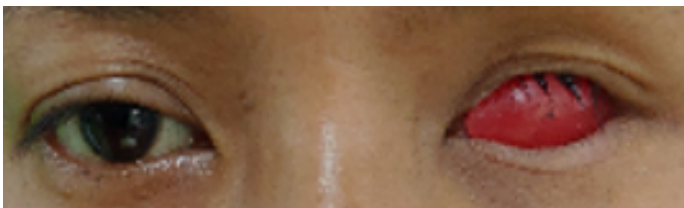


Figure 7. Try in of the sclera wax




Figure 8. try in of the acrylic sclera

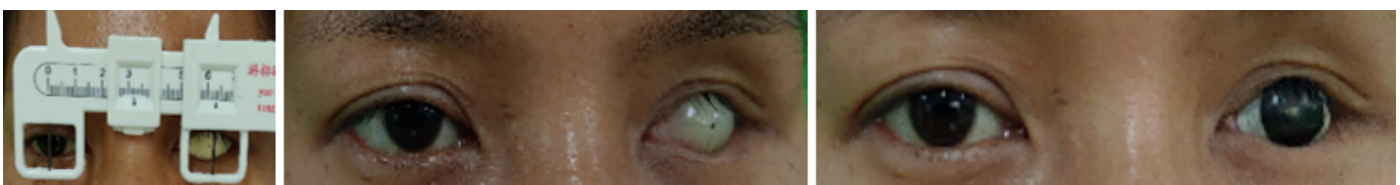


Figure 9. AFI working principle

eye socket to evaluate color, size, comfort, superior and inferior eyelid support, and eye movement [figure 8](#).

Determination of the location of the iris using the pupillary distance ruler (PD ruler) [figure 9A](#), after try in the sclera, instruct the patient to look forward with distraction technique. Positioning the instrument on the patient by placing the notch on the bridge of the nose and adjusting it to accommodate the eye within the ocular opening. The patient was asked to hold the eye position in a normal conversational gaze. Measure the orientation, pupillary distance, and medio-lateral dimensions of the original iris on a graded scale until a consistent measurement is achieved. Then the measurement was transferred to the sclera pattern by marking it using a marker as the midpoint of the pupil which becomes the midpoint of the iris [figure 9B](#). Using a drawing compass, a circle the size of a 12 mm circle is formed. The marked circles are darkened using a marker [figure 9C](#).

Iris coloring uses water color printing paper that has been shaped in a circle with A diameter of 12 mm according to the patient's eye [figure 10](#). The coloring was done with oil paints (reeves oil colors) using a 0.00 size brush. After coloring was done, coat the iris with monopoly syrup to prevent air trapping during curing, which causes color distortion of the iris.

Investing the iris on the sclera, a hole was made in the acrylic sclera according to the area of the marking that had been done. A hole was made as deep as 4 mm as a place for the iris to be placed. Reducing the thickness of the 2 mm thick facial surface by following the adjusted convex shape. Next, the iris was made into the sclera, by placing the iris into the hole that has been formed. Making blood vessels in the sclera with red threads. The sclera was placed back in the flask, to which CMS (Apollon Sep, Yamahachi Dental MGF, CO, Japan) was applied first. Clear liquid and powder PMMA were mixed after entering the dough stage and put into the mold. Then it was pressed and the excess was removed after that it cured for approximately 1 hour. Then, finishing and polishing were done [figure 11](#).

The important thing that must be considered when insertion of the custom ocular prosthesis is adaptation of the ocular prosthesis into the eye socket [figure 12](#), the ocular prosthesis can support the eye socket without pain and the ocular prosthesis movement can follow the movement of the eye muscles. Post-insertion instructions are placement and removal of the ocular prosthesis with clean hands, the ocular prosthesis is removal at night and soaked with antibacterial solution and periodic follow-up every year at the prosthodontist.

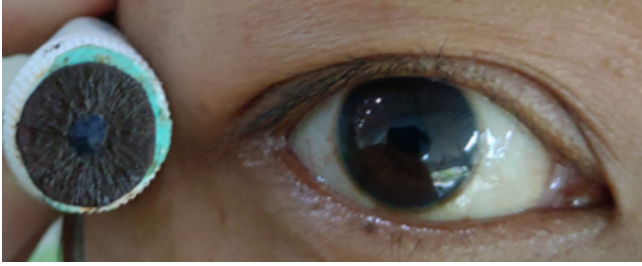


Figure 10. Iris Coloring

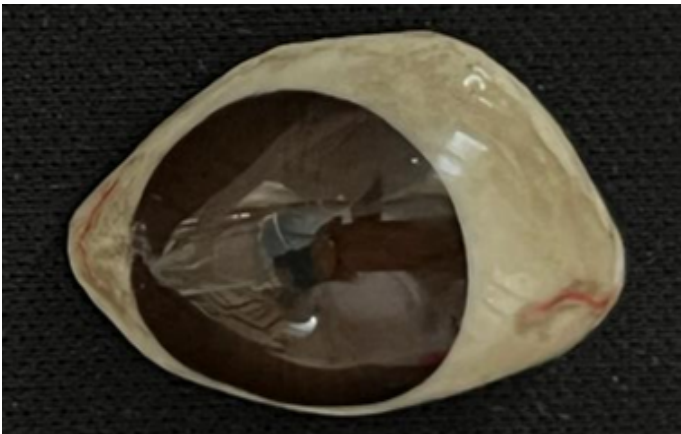

Figure 11. Custom ocular prosthesis

Discussion

Enucleation surgery can lead to various complications including wound dehiscence, postoperative infection, implant migration or extrusion, and most importantly, post-enucleated socket syndrome. According to the literature, post-enucleated socket syndrome is a relatively frequent complication following enucleation. Volume loss due to removal of the eyeball is a major cause of post-enucleated socket syndrome. The management of post-enucleated socket syndrome can be surgical or conservative treatment.⁵ The conservative treatment is the fabrication of a custom ocular prosthesis because the results obtained are very satisfactory, both in terms of aesthetics and retention.

Custom ocular prosthesis is a good option when reconstruction with surgery or the use of implants is not possible or affordable.² A custom ocular prosthesis made of acrylic resin is a substitute for the eyeball. Currently there are three types of acrylic resin prosthesis in use; stock ocular prosthesis, prefabricated ocular prosthesis modified by various methods, and custom ocular prosthesis made from eye socket impres-

sion.^{6,7} The most commonly used is the custom ocular prosthesis creation technique.⁷ Disadvantages of stock ocular prosthesis range from incompatibility to infection of the soft tissue of the eye socket. In comparison, custom ocular prosthesis made of acrylic resin are more precise because they can mimic the color, shape, size, and movement of the natural eye.^{6,9} It is thus aesthetically superior due to the adjustment and impression of the tissue in the socket obtained before the ocular prosthesis is made.^{1,7}

In the case of a shallow eye socket, the main challenge is to obtain an adequate impression to improve the retention. Allen has described in the literature how to deal with various socket deformities using a modified impressions technique.¹ In this case, a one-step impressions technique was carried out, without performing anatomical impressions because the old custom ocular prosthesis was duplicated to create a custom impression tray as introduced by Miller.²⁻⁴ This reduces the number of patient visits to the clinic. To get an accurate impression of the socket, polyvinyl siloxane impression material with light body consistency is used.¹⁰

The old custom ocular prosthesis was duplicated to make a custom impression tray and modified by adding a rod to the facial surface. The purpose of the duplication is to obtain an impression of the old custom ocular prosthesis, so that the impression can be made using the duplicated custom ocular prosthesis without damaging or changing the old prosthesis. The old custom ocular prosthesis can be used while waiting for the new custom ocular prosthesis to be fabricated. The addition of the rod on the custom impression tray worked as a handle to maintain the stability of the tray during movement. The rod can be adjusted to smaller sizes, making it easier to record the inner palpebral of the socket during closing.

Another challenging and critical procedure in the fabrication of an ocular prosthesis is to paint the iris and to position the iris in an ideal symmetrical position.² The iris was painted using oil painting. According to Fernandes, oil painting has excellent chromatic stability and is significant to be used in artificial iris painting for ocular prosthesis polymerized by microwave energy, regardless of color, when compared to other paintings.¹¹ Positioning of the iris is using the PD ruler. The PD ruler has range from 20 to 40 millimetres, which helps in obtaining precise and accurate orientation of the iris. Moreover, it requires less chair side, less skill, easy to obtain and an inexpensive device. This is really advantageous over visual assessment it can be considered easier than the graph grid method because graph cutting and positioning is difficult and time consum-

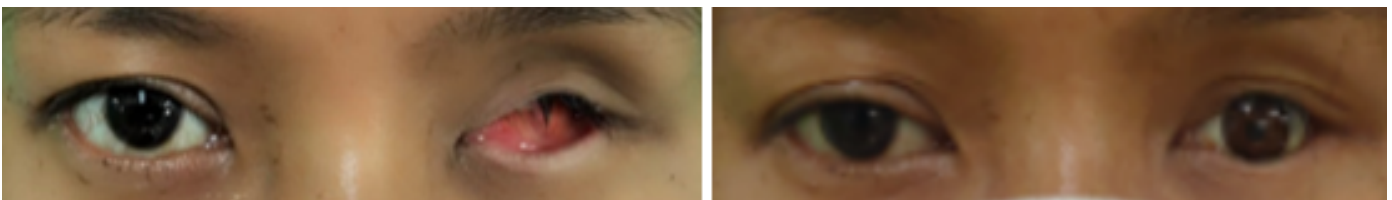

Figure 12. A. before insertion of the custom ocular prosthesis, B. After insertion of the custom ocular prosthesis

ing. Adjusting the scale for a distance between pupil is also a time-consuming and relatively difficult procedure.⁹

Conclusion and Suggestion

The reduced or loss of volume due to enucleation poses a challenge to prosthodontists in achieving a retentive ocular prosthesis when implants are not the treatment of choice. An accurate impression is critical to the success of this particular ocular prosthesis. The purpose is not only obtaining the retention of the prosthesis, but also the ability to restore an aesthetic appearance, a symmetrical face, and comfort to the patient. Thus, the custom ocular prosthesis increases the patient social acceptance, self-confidence, and overall quality of life. This case report describes how to achieve the retention in a custom ocular prosthesis by utilizing the patient's old custom ocular prosthesis as a custom tray.

The difficulty encountered in this impression technique was the possibility of inadequate amount of impression material during the impression procedure. The impression material could not be placed in bulk because of the flat surface of the impression tray. Another disadvantage of this technique was the absent of escape holes in the design of the custom impression tray, which resulted in excessive pressure on the eye socket, which could compromise impression accuracy. The authors suggested the use of escape holes as a place for excess impression material to flow and the use of a syringe to carry the impression material directly into the eye socket.

References

1. Raizada K, Rani D. Ocular prosthesis. *Contact Lens Anterior Eye*. 2007;30(3):152–62.
2. Report AC. Acrylic Based Individual Ocular Prosthesis A Case Report. 2021;33(1CoSIHSN 2020):280–2.
3. Y. Ravi, K. Srinivas, Singht M. A New Procedure for the Fabrication of Custom Ocular Prosthesis – A Case Report. *Dental Journal of Advance Studies*. 2013.
4. Arif F, Ariyani A, Tamin HZ. Modified functional ocular impression of post-enucleation socket: A case report. *Indones J Prosthodont*. 2021;2(2):61–5.
5. Kamble VB. Prosthetic Correction of Postenucleation Socket Syndrome: A Case Report. *J Indian Prosthodont Soc*. 2014;14:172–6.
6. Kaur S, Yadav R, Aggarwal H, Jurel S, Kumar P, Baslas V. Basic principles of rehabilitation for lost eye: A dentist s perspectives. *J Sci Soc*. 2015;42(2):99.
7. Ragher M, Chatterjee A. Ocular Prosthesis- A Simplified Technique. 2014;1(12):2–4.
8. Quaranta-Leoni FM. Treatment of the anophthalmic socket. *Curr Opin Ophthalmol*. 2008;19(5):422–7.
9. Paul L, Ravichandran R, K HK, Nair V V. Customized Ocular Prosthesis Simplified Using Pupillary Distance Ruler - A Case Report. 2020;9(4):2018–21.
10. Manoj SS. Modified Impression Technique for Fabrication of a Custom Made Ocular Prosthesis. *Anaplastology*. 2014;03(02):2–3.
11. Fernandes AÚR, Goiato MC, Batista MAJ, dos Santos DM. Color alteration of the paint used for iris painting in ocular prostheses. *Braz Oral Res*. 2009;23(4):386–92.