

## Considerations in occlusal vertical dimension rehabilitation

**Mariska Juanita, Eri Hendra Jubhari**

Department of Prosthodontics

Faculty of Dentistry, Hasanuddin University

Makassar, Indonesia

Correspondence author: **Mariska Juanita**, E-mail: [mariskajuanita@gmail.com](mailto:mariskajuanita@gmail.com)

### ABSTRACT

The vertical dimension is one of the important aspects that affect facial appearance, because it is related in facial height ratio. The vertical occlusal dimension is the height of the lower face measured from two points (infra-nasal and gnation points) when the maxillary and mandibular teeth were occlusion in the maximum intercuspal position. In complex cases, tooth wear can result in a decrease in facial height because the predominant wear on the anterior teeth encourages downward movement of the condyles when the intercuspal is maximum so that the vertical dimension decreases. In addition, factors that cause a decrease in the vertical dimension are loss of posterior teeth accompanied by skeletal disharmony or accompanied by tooth abrasion and migration. The purpose of this paper is to explain how to restore the decreased occlusal vertical dimensions. Things that need to be considered are divided into two, extraorally and intraorally. Extraoral considerations are in the form of a large reduction in OVD, facial esthetics and conditions of the temporomandibular joint. The parameters considered intraoral were the remaining tooth structure and occlusion. It was concluded that tooth wear due to functional and parafunctional activities can result in dimensional changes in facial morphology as well as a decrease in the occlusal vertical dimension. Correct OVD rehabilitation is an important factor in the success of rehabilitation treatment.

**Keyword:** occlusal vertical dimension, tooth wear, occlusal vertical dimension rehabilitation

### INTRODUCTION

The vertical dimension (VD) is defined as the distance between two selected anatomical landmarks, usually one on the tip of the nose and the other upon the chin.<sup>1</sup> The VD is one of the important aspects that affect facial appearance, because it is related to facial height ratio. The occlusal vertical dimension (OVD) is the vertical dimension measured when mandibular teeth are occluded with the maxillary teeth.<sup>2</sup>

Loss of tooth structure due to functional activities or tooth wear is a physiological process that will occur over time. Attrition, abrasion, erosion and parafunctional habits that occurs excessively will damage the occlusal surface.<sup>3,4</sup> Basically, mastication system will adapt to tooth wear due to functional activity through the dentoalveolar compensatory mechanism, which is the formation of eruptive pressure that encourages vertical movement of the teeth and alveolar until it reaches a resistance equal to the eruptive pressure.<sup>5,6</sup>

This vertical movement will trigger a constant change in muscle contraction and affect the temporomandibular joint (TMJ), rotational movement of the condyles from the horizontal axis to the maximum intercuspal position decrease OVD.<sup>6</sup> The decreasing of OVD affect facial appearance due to shortened height in the lower third of the face, lip intrusion, decreased nasolabial angle and also phonetic and mastication dysfunction.<sup>3</sup>

The determination of the treatment plan is strongly influenced by an understanding of the phy-

siology and biomechanics of the vertical dimension. Lack of understanding can lead to iatrogenic damage to the teeth as well as undiagnosed TMD.<sup>6</sup>

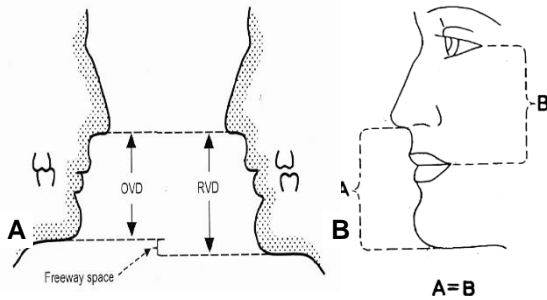
In decreased VD cases involving excessive loss of tooth structure and massively affect teeth in the arch, it is necessary to consider restoring the OVD by adding it because it can create space for fixed restorative, improve anterior tooth relations, restore physiological VD as well as minimize invasive procedures such as crown lengthening surgery.<sup>5</sup>

The purpose of this paper is to find out how to restore the decreased OVD and consideration in determining the treatment plan.

### LITERATURE REVIEW

The Glossary of Prosthodontic Terms defines the vertical dimension as distance between the two anatomical marks, one point on the upper half facial height and the other one in the lower half facial part. The first anatomical landmark is located on the tip of the nose and the other upon the chin, where one of the points is on movable tissue and the other is on fixed tissue.<sup>1</sup>


The OVD is the height of the lower face measured from two points (infra-nasal and gnation points) when the maxillary and mandibular teeth are occluded in the maximum intercuspal position. The vertical dimension (RVD) is the VD measured when the mandible is in a rest position. The interocclusal distance when the maxilla and mandible in rest position or the difference between RVD and OVD is called free way space (FWS).<sup>7</sup>



**Figure 1A** Schematic of the OVD, RVD and FWS; **B** Schematic comparison of distances between craniofacial landmarks (Source: Raj N, Meshram A, Mulay S. Review on methods of recording vertical relations. *Evolution Med Dent Sci* 2013; 2 (12): 1779–84.<sup>8</sup>

Mandibular resting position is defined as the mandibular position when the head is in upright position and the masticatory muscles are in a tonic contraction state and the condyles are in a neutral position. The value of the OVD is obtained by subtracting 2-4 mm from the obtained rest position value. The value of the resting position is measured from two anatomical points on the face (two dots), the tip of all the nose and chin, using measuring instruments such as the Willis gauge, callipers, rulers (mm) and digital calipers.<sup>9</sup>

The method for getting the mandible in a resting position is that the patient is instructed to say "M" and the lips are relaxed. In addition to this method, the patient can also be instructed to swallow when position the mandible in a relaxed manner. The disadvantage of measuring vertical dimensions based on mandibular resting position is that the position of the mandible can be influenced by many factors such as functional habits, head position, lip activity, anxiety and fear and other disorders involving the mandibular motor complex.<sup>8,9</sup>



**Figure 2** Willis bite gauge (Source: Raj N, Meshram A, Mulay S. Review on methods of recording vertical relations. *Evolution Med Dent Sci* 2013; 2 (12): 1779–84.<sup>8</sup>

Craniofacial parameters can be used to estimate the height of the lower third of the face, the distance between nasal septum (Sn) to the base

of the chin (Me) and the distance from the tip of the nose (N) and the tip of the chin (Gn) is the distance used to determine the OVD. Comparing the distance formed between craniofacial landmarks makes it possible to detect if there is a decrease in OVD. Nagpal et al evaluated the reliability of this measurement and concluded that the distance from the outer eye corner to the lip corner and the distance from the outer eye corner to the tragus had a significant correlation with the N-distance. Gn so that this can be a parameter if there is a change in the OVD by comparing the two distances.<sup>8,9</sup>

Evaluation of OVD based on facial esthetics is seen from the balance ratio of the lower third of the face. The ideal OVD shows a face that is not taut with the lips slightly exposed. The appearance of the face becomes more tense, facial elongation is often accompanied by incompetent lips indicating increased OVD. A lowered mouth angle and a lower vermilion rim are associated with decreased OVD.<sup>2,10</sup> This method is effective for use in patients who are young to middle age because the facial tone is still in good condition. The reliability of this method is reduced when applied to patients whose facial tone is weakening and lips are incompetent.<sup>9</sup>

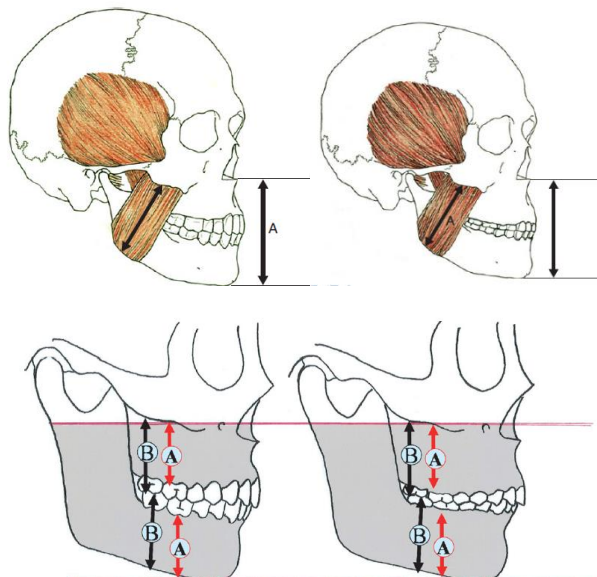
This method utilizes anatomical points on the skeletal via cephalometric tracing to determine the VD and maxillomandibular relations. This method is accurate but requires adequate radiographs and the radiation generated makes the application of this method limited. Electromyography (EMG) can also be used to determine VD, this tool will record muscle activity, the value of minimal muscle activity indicates the mandible is in a resting position.<sup>2,9</sup>

The VD is basically influenced by the maxillomandibular relation which is formed from the repetitive contraction mechanism of the mandibular elevator muscle, so that the teeth will erupt at a distance formed from the maxillomandibular relation.<sup>6</sup>

Teeth have eruptive pressure that pushes the tooth to erupt until it reaches the same pressure resistance. If the resistance is greater than the eruptive pressure, the tooth will intrude, and vice versa if the eruptive pressure of the tooth is greater than the resistance of the mandibular elevation muscle, the tooth will extrude until it reaches the same resistive pressure.<sup>6</sup>

This maxillomandibular relationship is consistent because it is controlled by contraction of the mandibular elevator muscle so that there is a compensatory mechanism of the alveolar bone to maintain the maxillomandibular relationship in the event of tooth wear due to parafunctional habits,

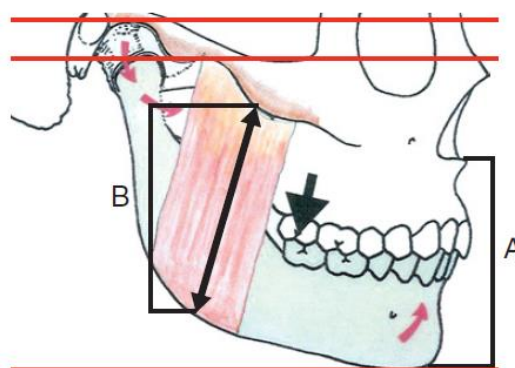
bruxism and clenching (Fig.3).<sup>6</sup> In complex cases, teeth can result in a decrease in facial height because the predominant wear on the anterior teeth encourages downward movement of the condyles when the intercuspals are maximum which leads to the VD decreases. In addition, factors that cause a decrease in the VD are loss of posterior teeth accompanied by skeletal disharmony or accompanied by tooth abrasion and migration (Fig.4).<sup>6,7</sup>



**Figure 3** Compensation mechanism of alveolar bone against tooth wear (right) due to abrasion, showing consistent length of mandibular elevator muscle during repetitive contraction (Source: Dawson PE. Functional occlusion-from TMJ to smile design. Missouri: Mosby; 2008. p33-56).<sup>6</sup>

In Fig.5A, the decrease in OVD is due to the rotation of the mandible in the anterior region with the axis at the condyles, while the loss of occlusion support in the posterior region causes movement of the mandible (rotation) with the axis at the most distal side of the remaining tooth.<sup>6</sup>

Changes in the VD that occur tend to encourage patients to feel insecure because they reduce



**Figure 4** Decrease in the VD due to changes in condyle position (Source: Dawson PE. Functional occlusion-from TMJ to smile design. Missouri: Mosby; 2008. p.33-56).<sup>6</sup>

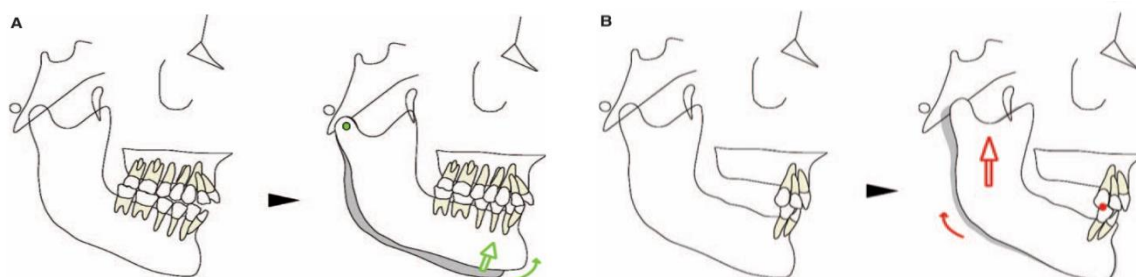
the aesthetic value of the face, in addition to that in the case of decreasing VD it results in facial disharmony, disruption of the TMJ that triggers lesions such as angular cheilitis.<sup>10</sup> Determination of a good treatment plan is necessary because errors in the treatment approach can affect the condition of the TMJ and the stomatognathic system.<sup>6</sup>

Excessive increase in VD can lead to pain in muscles and joints, functional disorders in the form of tense speech, difficulty swallowing, and chewing. Changes in the VD are made if you want to improve the occlusal relationship and prepare space for permanent restoration.<sup>6,12</sup>

Things that need to be considered are divided into two, extraorally and intraorally. Extraoral considerations are in the form of a large reduction in OVD, facial esthetics and conditions of the TMJ. The parameters considered intraoral were the remaining tooth structure and occlusion.<sup>2</sup>

**Measurement of the decreased OVD**

Evaluation is by measuring the interocclusal rest space (IORS), which is the reduction in the VD when the mandible is in a resting position and to the VD when the mandible is occluded. This



**Figure 5A** Decrease in OVD due to condyle rotation; **B** due to loss of posterior occlusion support (Source: Dawson PE. Functional occlusion-from TMJ to smile design. Missouri: Mosby; 2008. p33-56).<sup>6</sup>

This aims to determine the amount of additional VD that will be made. Physiologically, the IORS value is 2 mm, so if a value greater than 2 mm is obtained, it indicates a decrease in OVD and can be added safely.<sup>2,5</sup>

### Facial aesthetics

The determinants of facial esthetics are the sagittal profile, facial appearance, lip morphology and appearance of the teeth. Examination of the sagittal profile may reveal pseudoprogathy which is a sign of decreased OVD and mandibular overclosure. The results of cephalometry showed that the worn teeth caused a reduction in arch width and gonial angle, thus showing a pseudoprogathic appearance.<sup>2</sup>

### The state of the TMJ

Examination of TMJ before returning the VD is important in the form of examination of joint pain, mandibular movement and whether or not clicking. Comprehensive examination and treatment approaches need to be carried out, especially in patients with TMJ disorders, because the symptoms of TMJ neglect often detected because they are masked by the patient's discomfort during the adaptation period. Patients with TMJ disorders are treated with removable occlusal devices that function to stabilize the TMJ and increase the OVD prior to permanent restoration.<sup>2</sup>

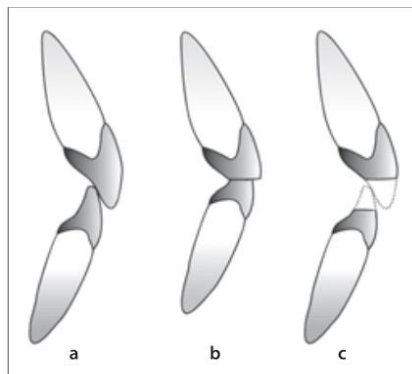
### The remaining tooth structure

The prognosis of the restoration depends on the amount of remaining tooth structure, measured by the VD between the edges of the preparation and the occlusal-axial angle line. The height of the preparation is a determinant of the retention and resistance of the restoration, the minimum recommended restoration height is 3-4 mm. If the clinical crown height of the tooth is inadequate, an alternative treatment, crown lengthening surgery (CLS), can be performed.<sup>2</sup>

### Occlusion

In the case of worn anterior teeth, the mandible tends to be in a more anterior position, by noting the horizontal position of the mandible when the centric and intercuspal relationships are maximum, adequate interincisal distance can be obtained for the restoration of the worn anterior tooth. Loss of posterior tooth support is also one of the main causes of decreased OVD. The clinical implication of this is that there is excess chewing pressure on the remaining anterior teeth, resulting in

potential wear. Decreased clinical crown height tends to render the incisal relationship edge to edge. This impairs esthetics and causes loss of anterior guidance. This condition requires the addition of a OVD in order to re-establish overjet and overbite and restore anterior guidance.<sup>2,5</sup>



**Figure 6** The consequences of worn teeth on the anterior relations (a) normal relations of the anterior teeth; (b) wearing of the anterior teeth makes the anterior relation edge to edge; (c) improvement of the anterior relation by increasing the OVD (Source: Abduo J. Safety of increasing vertical dimension of occlusion: a systematic review. *Quintessence Int* [Internet]. 2012; 43: 369-80. Available from: <http://www.ncbi.nlm.nih.gov/pubmed/22536588> (Accessed on 15 Sept 2020).<sup>5</sup>

### DISCUSSION

Rehabilitation of patients with worn tooth in the occlusal area is a complex treatment and a challenge in the field of dentistry. Teeth are prone to be worn and torn due to functional activity. But this condition can be worsened in cases of posterior tooth loss because the chewing load will be concentrated on the remaining anterior teeth resulting in occlusion disorders and parafunctional habits such as bruxism.

Bruxism is a parafunctional habit of grinding teeth, or a habit of unconsciously grinding, grinding teeth in addition to chewing movements of the mandible, thus triggering occlusal trauma. The cause of bruxism has not been specifically known with certainty, but several factors that influence, namely morphological factors such as dental occlusion, psychosocial factors such as stress and certain personality characteristics, pathophysiological factors (disease, trauma, genetics, smoking, alcohol, caffeine consumption, drugs) and sleep disorders (sleep apnea and snoring).<sup>3,6</sup>

When the mandible alternately moves laterally, the teeth will be subjected to large horizontal stresses, increasing the likelihood of breaking the tooth structure to the periodontal tissue. Bruxism also occurs in an eccentric position, resulting in an



uneven distribution of pressure but only on a few teeth, in contrast to performing functional activities where the mandible is in a centric position for occlusion. Worn tooth due to parafunctional habits were associated with the development of tooth sensitivity, a decrease in the height of the clinical crown and the possibility of a change in OVD. Loss of tooth structure does not directly result in loss of VD, so to determine whether there is a change in OVD, various aspects need to be considered such as how the occlusion of the posterior teeth, the level of tooth wear, phonetic evaluation of hissed sounds, interocclusal distance and facial appearance. The increase in OVD causes the teeth to contact when making a hissing sound, difficulty in closing the lips and difficulty in swallowing accompanied by pain, whereas if the OVD decreases, it shows excessive closure during occlusion, which disturbs the TMJ, excessive lip contact and angular cheilitis.<sup>3</sup>

The initial stage in the case of tooth wear in the anterior region, namely the return of the OVD, is performed to restore the height of the lower third of the face and establish an interocclusal distance to allow occlusal reconstruction, anterior and canine guidance. Several techniques can be used to measure OVD, but in this case using the Willis Method which states that the distance between the base of the nose to the chin (lower third of face) is equal to the distance from the corner of the lips to the commissure of the eye (middle third of face) when the teeth are in the maximum intercuspal position. Tools developed are shaped like the letter "L" since 1930 to facilitate this measurement. This method is the right technique, accurate and practical because it does not require expensive equipment and the use of the tool is easily understood by the operator.<sup>2,3,8</sup>

Restoration treatment still should not precede the return stage of OVD because it will be difficult for patients to adapt to the new OVD. Return of the OVD is done incrementally to allow movement of the condyles back to the centric position and to increase the OVD in the anterior region without in-

creasing contraction of the mandibular elevator muscle.<sup>3,11</sup> Gough and Setchell<sup>3</sup> stated that OVD returns with fixed interim dentures are more comfortable and provide better results than removable dentures.

The removable denture tends to make it difficult for patient to speak, is less aesthetically pleasing and causes symptoms that stem from the use of the removable denture, not because of an increase in OVD. The use of the OVD return method with fixed dentures can reduce cases involving parafunctional habits such as grinding and clenching, and become visible within 1-2 weeks of use.<sup>5</sup>

The period of adaptation of the patient to the new OVD is not definite, but the minimum interval period of 4 weeks will be evaluated for TMJ disorders, mastication, swallowing, speech and aesthetics. This is in line with Carisson et al<sup>3</sup> who stated that there was a decrease in muscle activity detected by EMG in the adaptation period of 1 month. Permanent restoration can be performed after the patient has adapted to the new OVD. It is necessary to return the OVD in patients with the habit of grinding teeth even though they are not accompanied by pain symptoms because this parafunctional habit can interfere with the aesthetics and function of the masticatory system.<sup>3</sup>

It was concluded that worn teeth due to functional and parafunctional activities can result in dimensional changes in facial morphology as well as a decrease in the OVD. Correct OVD rehabilitation is an important factor in the success of rehabilitation treatment, because decreasing OVD lead to tooth decay, muscle disorders, TMJ, ingestion, and phonetics disfunction. The VD rehabilitation currently tends to use fixed dentures because they have better aesthetics, adaptation and functional enhancement in patients. The use of removable dentures shows a complaint that is often misinterpreted because the complaints arising from the use of removable dentures are similar as complaints after the new OVD adaptation so that it becomes a complicating factor in evaluating patients during the adaptation period.

## REFERENCES

1. Ladda R, Kasat VO, Bhandari AJ. A new technique to determine vertical dimension of occlusion from anthropometric measurement of interpupillary distance. *J Clin Exp Dent* 2014; 6 (4): 395–9.
2. Abduo J, Lyons K. Clinical considerations for increasing occlusal vertical dimension: A review. *Aust Dent J* 2012; 57 (1): 2–10.
3. Health D, Disorders O. Re-Establishment of an occlusal vertical dimension: a case report 2018; 9 (1). 95-9
4. Gopi Chander N, Venkat R. An appraisal on increasing the occlusal vertical dimension in full occlusal rehabilitation and its outcome. *J Indian Prosthodont Soc* 2011; 11 (2): 77–81.
5. Abduo J. Safety of increasing vertical dimension of occlusion: a systematic review. *Quintessence Int* [Internet]. 2012; 43: 369-80. Available from: <http://www.ncbi.nlm.nih.gov/pubmed/22536588> (Accessed on 15 Sept 2020)

6. Dawson PE. Functional occlusion - from TMJ to smile design. Missouri: Mosby; 2008. p33-56.
7. Rebibo M, Darmouni L, Jouvin J, Orthlieb JD. Vertical dimension of occlusion: the keys to decision. *Int J Stomatol Occlusion Med* 2009; 2 (3): 147–59.
8. Raj N, Meshram A, Mulay S. Review on methods of recording vertical relations. *Evolution Med Dent Sci* 2013; 2: 1779–84.
9. Alhaji MN, Khalifa N, Abduo J, Amran AG. Determination of occlusal vertical dimension for complete dentures patients: an updated review. *J Oral Rehabil* 2017; 896–907.
10. Discacciati JAC, de Souza EL, Vasconcellos WA, Costa SC, Barros VM. Increased vertical dimension of occlusion: Signs, symptoms, diagnosis, treatment and options. *J Contemp Dent Pract* 2013; 14 (1): 123–8.
11. Bataglioni C, Hotta TH, Matsumoto W, Ruellas CVO. Reestablishment of occlusion through overlay removable partial dentures: a case report. *Braz Dent J* 2012; 23: 172–4.
12. Bloom DR, Padayachy JN. Increasing occlusal vertical dimension - why, when and how. *Br Dent J* 2006; 200: 251–6.